

Inner Arm Reduction

Introduction

For a variety of reasons hanging skin on the posterior arm causes grief to many people, especially when it is considered a sign of ageing. Obesity, weight loss, skin redundancy, with loss of normal skin elasticity and collagen thinning, render the subcutaneous tissue prone to gravitate and embarrass the individuals concerned. The vast majority of individuals seeking surgical correction are women and they tend to conceal the “bingo wings” area with extended sleeve clothing, which is sometimes inappropriate.

Management

Occasionally the loose ageing skin of upper arm shows anteriorly as wrinkles and folds. These may be improved, certainly in the short- term, by using vacuum rollers, fillers and even autologous fat graft.

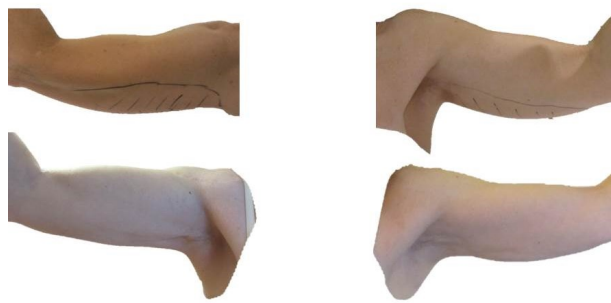
The classical “bingo wings” are generally managed surgically and the options are either liposuction alone, surgical excision of redundant skin alone, or most commonly by a combination of both liposuction and as limited a skin excision as possible. If the skin is relatively elastic, then liposuction through one or two small scars are often preferable to a major and visibly obvious scar.

Excision involves a scar and this has to be fully explained to the patient because the extent of the scar will vary according to the presentation. It is obviously preferable to try to elevate the arm with a simple elliptical skin excision in the axilla, but this is often disappointing. Any longitudinal scar down the medial and postero-medial aspect of the arm will be visible, especially with arm elevation, but this is usually necessary. The resultant axial scar will contract and often become hypertrophic, taking many months to settle down under a rigid scar control policy.

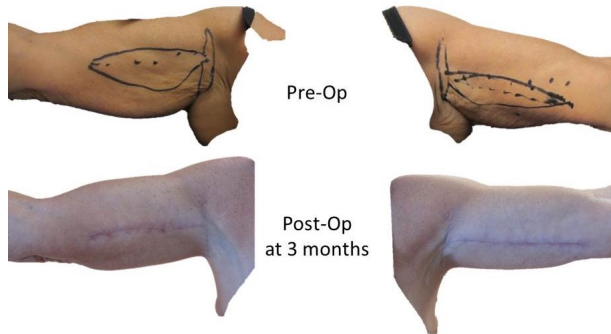
Occasionally a delayed Z-plasty under local anaesthetic can be used to remove tension upon the scar and aid the speed of maturation. A pressure support garment may be required.

Surgical Technique

An effort to retain Scarpas fascia but remove the redundant fatty tissue using liposuction enables the Surgeon to safely excise a significant amount of tissue. Wounds are closed in layers and drains are rarely needed. The procedure may take 2 to 3 hours.



Inner Arm Reduction using Liposuction alone



Inner Arm Reduction showing Skin Excision markings

Complications

Bleeding, seroma, infection and poor wound healing are relatively uncommon risks in the initial post-operative period. Scar control and a mild degree of laxity always returns, particularly if there has been significant swelling post-operatively. Whilst a degree of lymphoedema or hand swelling will occur if the closure is too tight, or support dressings are inappropriate, this usually settles and is not a common outcome over the long term.